Extract of Patient Record

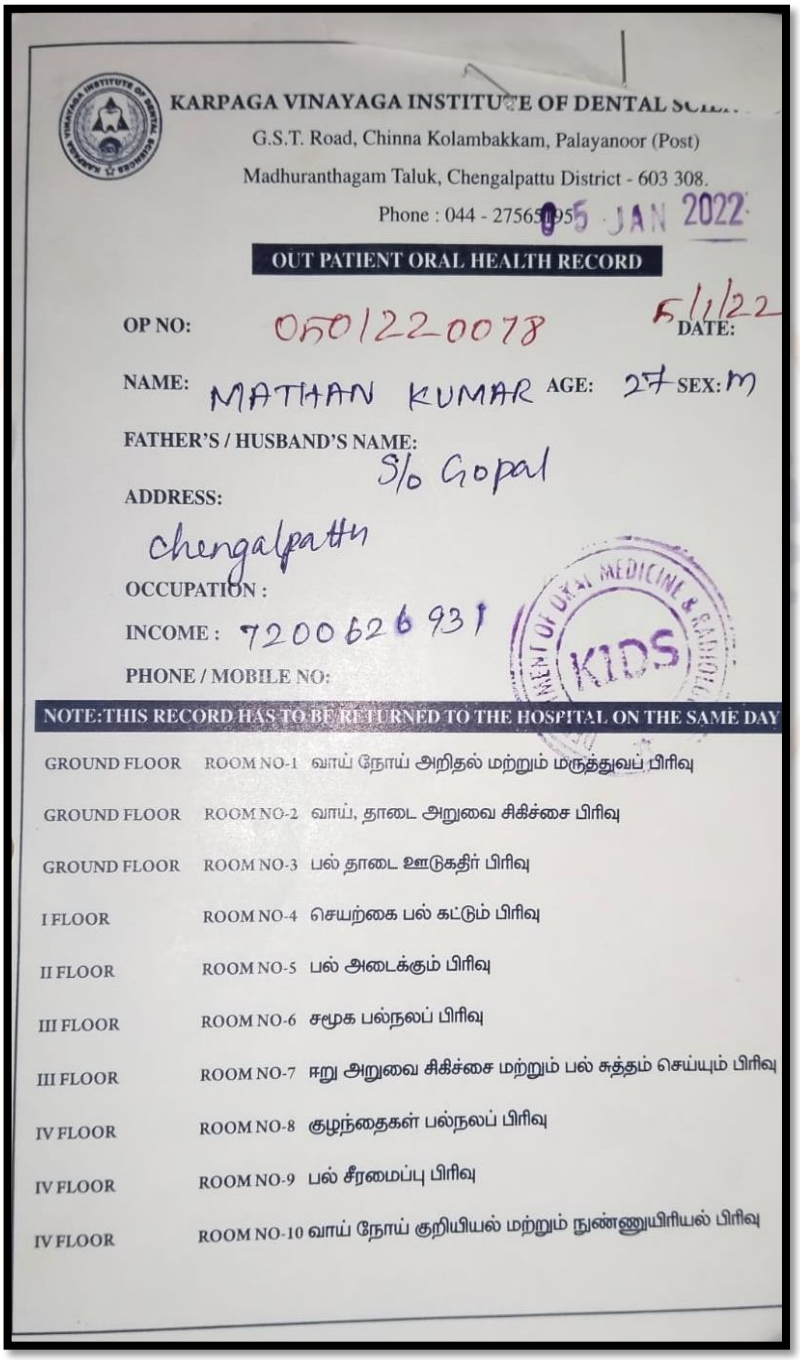

KARPAGA VINAYAGA INSTITUTE OF DENTAL SCI...
G.S.T. Road, Chinna Kolambakkam, Palayanoor (Post)
Madhuranthagam Taluk, Chengalpattu District - 603 308.
Phone : 044 - 27565195

05 JAN 2022

OUT PATIENT ORAL HEALTH RECORD

OP NO: OKO/220078 DATE: 5/1/22

NAME: MATHAN KUMAR AGE: 27 SEX: M

FATHER'S / HUSBAND'S NAME: S/o Gopal

ADDRESS: Chengalpattu

OCCUPATION :

INCOME : 7200626931

PHONE / MOBILE NO:

DEPT OF ORAL MEDICINE & RADIOLOGY KIDS

NOTE:THIS RECORD HAS TO BE RETURNED TO THE HOSPITAL ON THE SAME DAY

GROUND FLOOR	ROOM NO-1	வாய் நோய் அறிதல் மற்றும் மருத்துவப் பிரிவு
GROUND FLOOR	ROOM NO-2	வாய், தாடை அறுவை சிகிச்சை பிரிவு
GROUND FLOOR	ROOM NO-3	பல் தாடை ஊடுகதிர் பிரிவு
I FLOOR	ROOM NO-4	செயற்கை பல் கட்டும் பிரிவு
II FLOOR	ROOM NO-5	பல் அடைக்கும் பிரிவு
III FLOOR	ROOM NO-6	சமூக பல்நலப் பிரிவு
III FLOOR	ROOM NO-7	ஈறு அறுவை சிகிச்சை மற்றும் பல் சுத்தம் செய்யும் பிரிவு
IV FLOOR	ROOM NO-8	குழந்தைகள் பல்நலப் பிரிவு
IV FLOOR	ROOM NO-9	பல் சீரமைப்பு பிரிவு
IV FLOOR	ROOM NO-10	வாய் நோய் குறியியல் மற்றும் நுண்ணுயிரியல் பிரிவு

Dean
KARPAGA VINAYAGA INSTITUTE OF DENTAL SCIENCES
G.S.T. Road, Chinna Kolambakkam,
Palayanoor Post, Madhuranthagam Taluk,
Chengalpattu District-603 308.

KARPAGA VINAYAGA
INSTITUTE OF DENTAL SCIENCES
GST Road, Chinna Kolambakkam, Padalam (po), Chengalpattu (dt)
Madhuranthagam(tk), Tamilnadu 603 308

Extract of Patient Record

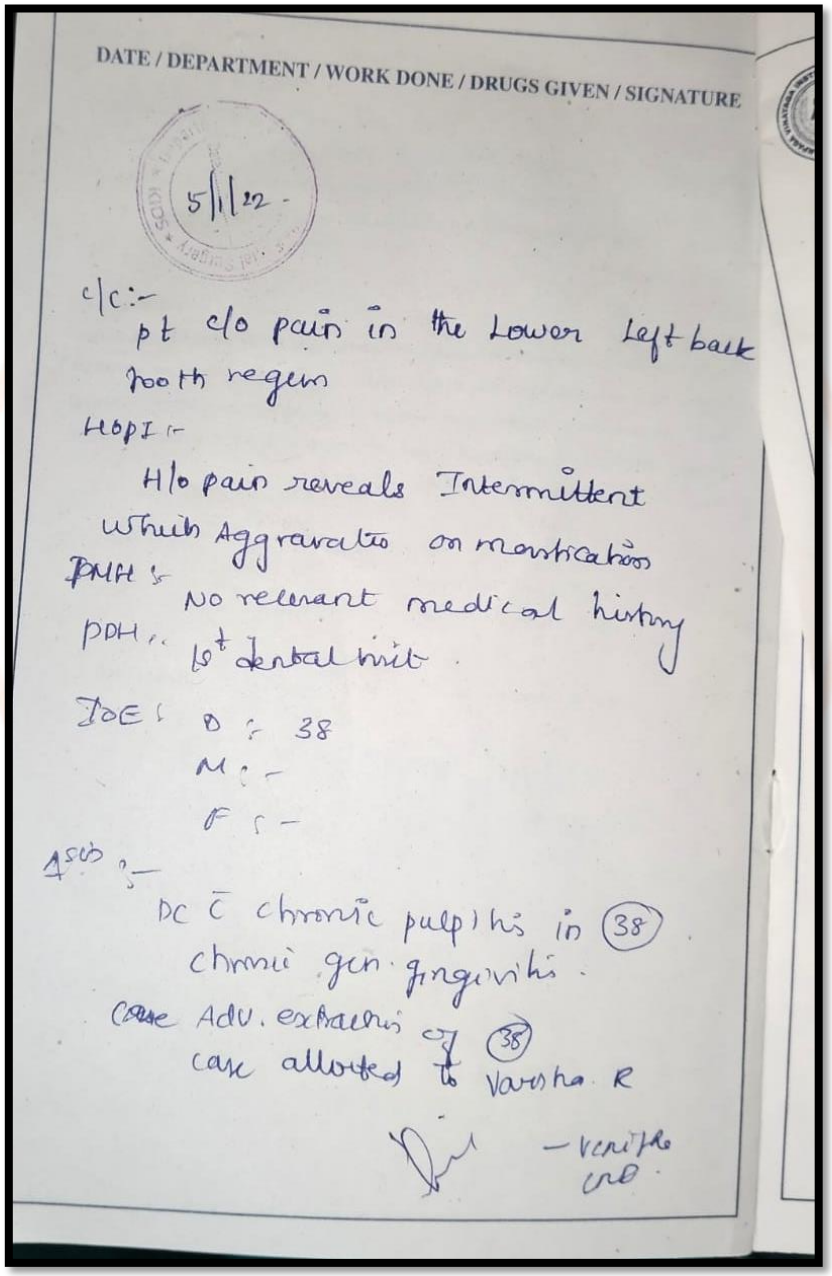

DATE / DEPARTMENT / WORK DONE / DRUGS GIVEN / SIGNATURE

5/1/22.

c/c:-
pt c/o pain in the Lower Left back tooth region

HOPI:-
H/o pain reveals Intermittent which Aggravates on mastication

PMH:- No relevant medical history

PDH:- 1st dental visit.

IOE: D:- 38
M:-
F:-

Asis:-
DC c̄ chronic pulpitis in (38)
chronic gen. gingivitis.

Case Adv. extraction of (38)
case allotted to Varsha R

— verified
cnd.

Dean
KARPAGA VINAYAGA INSTITUTE OF DENTAL SCIENCES
G.S.T. Road, Chinna Kolambakkam,
Palayanoor Post, Madhuranthagam Taluk,
Chengalpattu District-603 308.

Extract of Patient Record

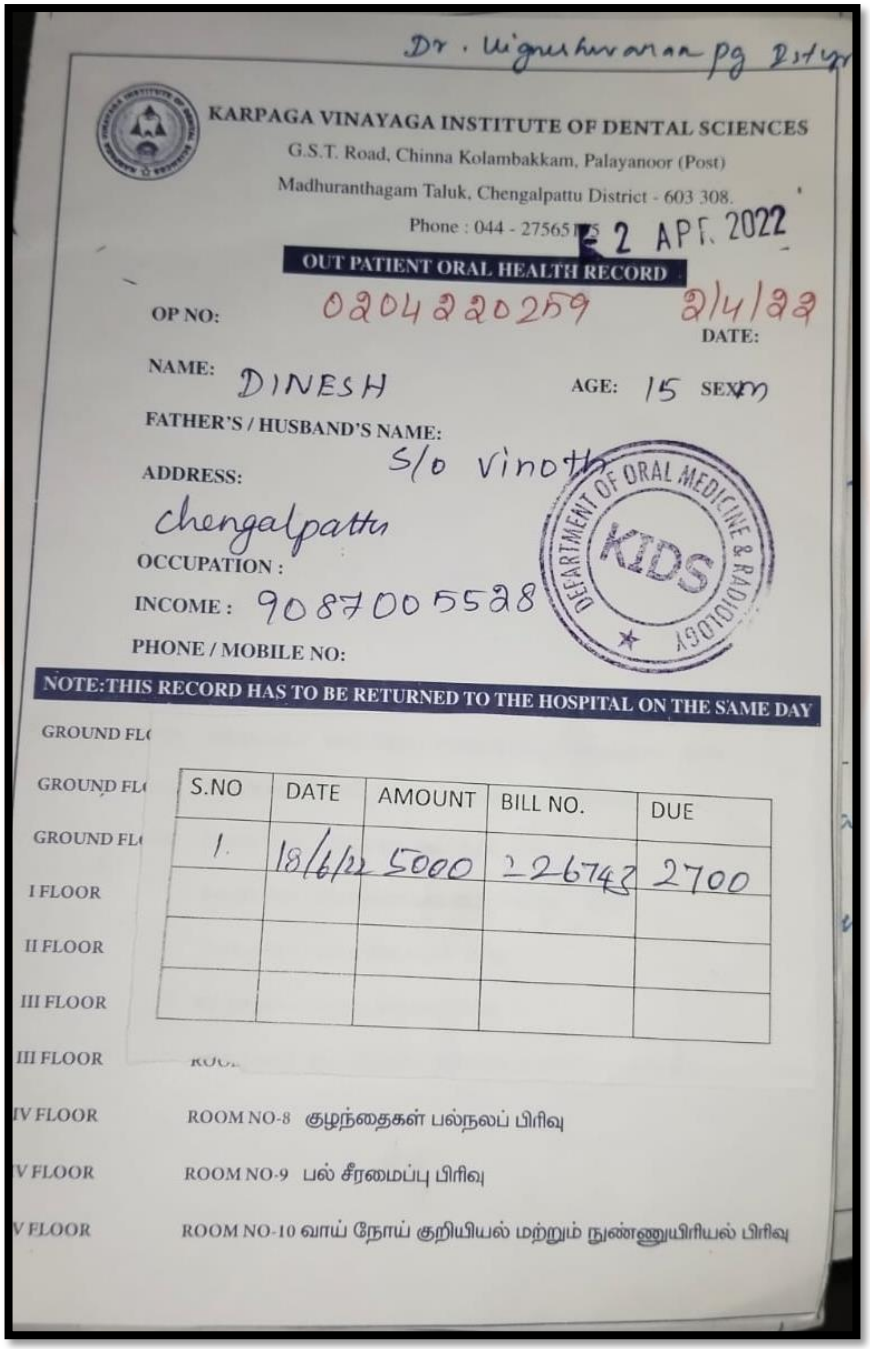

Dr. Vigneshwaran pg Dstyr

KARPAGA VINAYAGA INSTITUTE OF DENTAL SCIENCES
G.S.T. Road, Chinna Kolambakkam, Palayanoor (Post)
Madhuranthagam Taluk, Chengalpattu District - 603 308.
Phone : 044 - 27565 [illegible]

2 APR 2022

OUT PATIENT ORAL HEALTH RECORD

OP NO: 0204220259 DATE: 2/4/22

NAME: DINESH AGE: 15 SEX M

FATHER'S / HUSBAND'S NAME:

ADDRESS: S/o Vinoth
Chengalpattu

OCCUPATION :

INCOME : 9087005528

PHONE / MOBILE NO:

DEPARTMENT OF ORAL MEDICINE & RADIOLOGY KIDS

NOTE:THIS RECORD HAS TO BE RETURNED TO THE HOSPITAL ON THE SAME DAY

GROUND FL
GROUND FL
GROUND FL
I FLOOR
II FLOOR
III FLOOR
III FLOOR
IV FLOOR
V FLOOR
V FLOOR

S.NO	DATE	AMOUNT	BILL NO.	DUE
1.	18/4/22	5000	226743	2700

ROOM NO-8 குழந்தைகள் பல்நலப் பிரிவு

ROOM NO-9 பல் சீரமைப்பு பிரிவு

ROOM NO-10 வாய் நோய் குறியியல் மற்றும் நுண்ணுயிரியல் பிரிவு

Dean
KARPAGA VINAYAGA INSTITUTE OF DENTAL SCIENCES
G.S.T. Road, Chinna Kolambakkam,
Palayanoor Post, Madhuranthagam Taluk,
Chengalpattu District-603 308.

KARPAGA VINAYAGA
INSTITUTE OF DENTAL SCIENCES
GST Road, Chinna Kolambakkam, Padalam (po), Chengalpattu (dt)
Madhuranthagam(tk), Tamilnadu 603 308

Extract of Patient Record

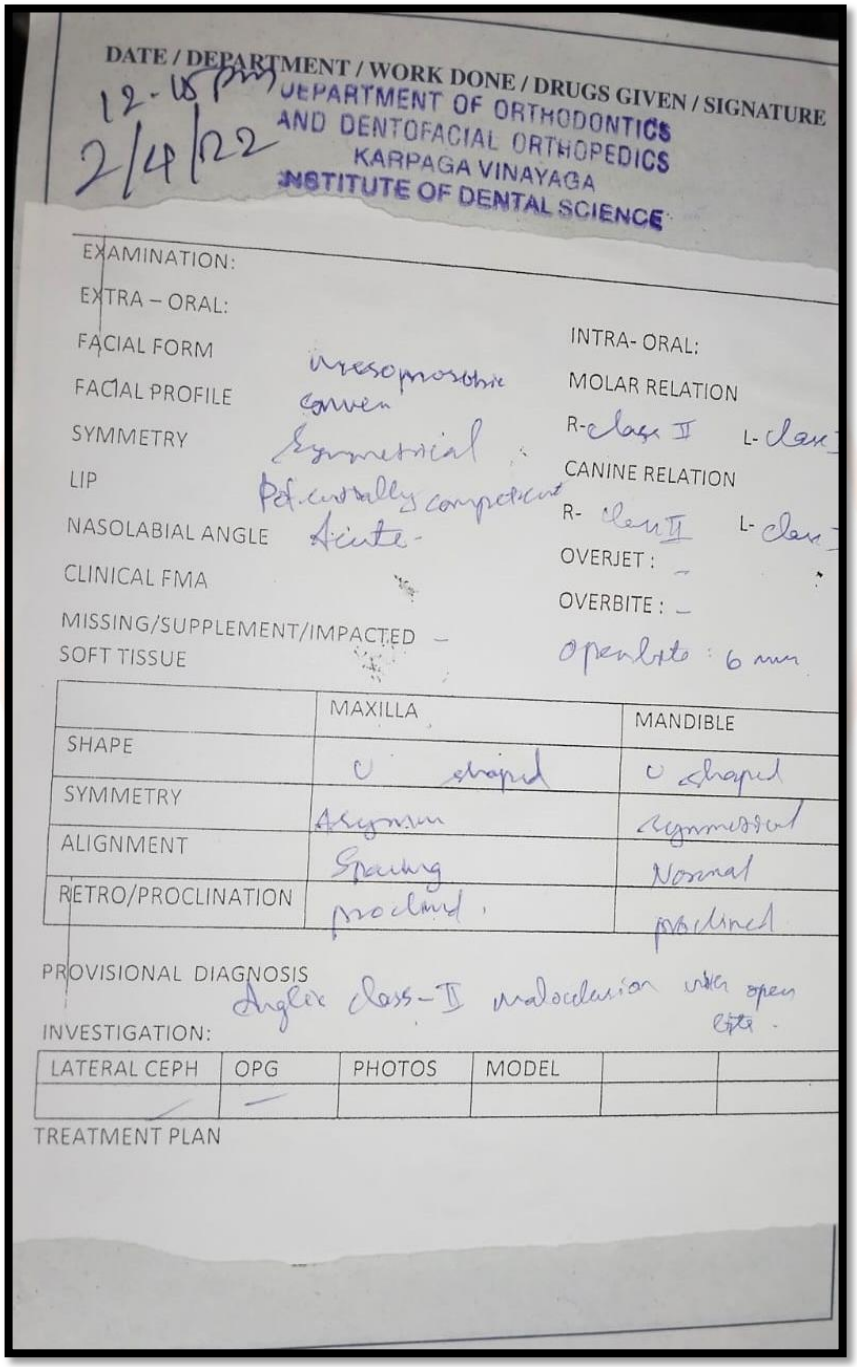

DATE / DEPARTMENT / WORK DONE / DRUGS GIVEN / SIGNATURE

12-15 pm
2/4/22

DEPARTMENT OF ORTHODONTICS AND DENTOFACIAL ORTHOPEDICS
KARPAGA VINAYAGA INSTITUTE OF DENTAL SCIENCE

EXAMINATION:

EXTRA – ORAL:

FACIAL FORM: mesoprosopic convex
FACIAL PROFILE
SYMMETRY: Symmetrical
LIP: Pot. cronally competent
NASOLABIAL ANGLE: Acute
CLINICAL FMA
MISSING/SUPPLEMENT/IMPACTED –
SOFT TISSUE

INTRA- ORAL:

MOLAR RELATION
R- class II L- class
CANINE RELATION
R- class II L- class
OVERJET : –
OVERBITE : –
Openbite : 6 mm

	MAXILLA	MANDIBLE
SHAPE	U shaped	U shaped
SYMMETRY	Asymm	Asymmetrical
ALIGNMENT	Spacing	Normal
RETRO/PROCLINATION	proclined	proclined

PROVISIONAL DIAGNOSIS: Angles class-II malocclusion with open bite.

INVESTIGATION:

LATERAL CEPH	OPG	PHOTOS	MODEL		
✓	—				

TREATMENT PLAN

Dean
KARPAGA VINAYAGA INSTITUTE OF DENTAL SCIENCES
G.S.T. Road, Chinna Kolambakkam,
Palayanoor Post, Madhuranthagam Taluk,
Chengalpattu District-603 308.